

NEW YORK STATE CYTOHEMATOLOGY PROFICIENCY TESTING PROGRAM
Glass Slide - November 2014

Results from this proficiency test event are available at:
<http://www.wadsworth.org/chemheme>

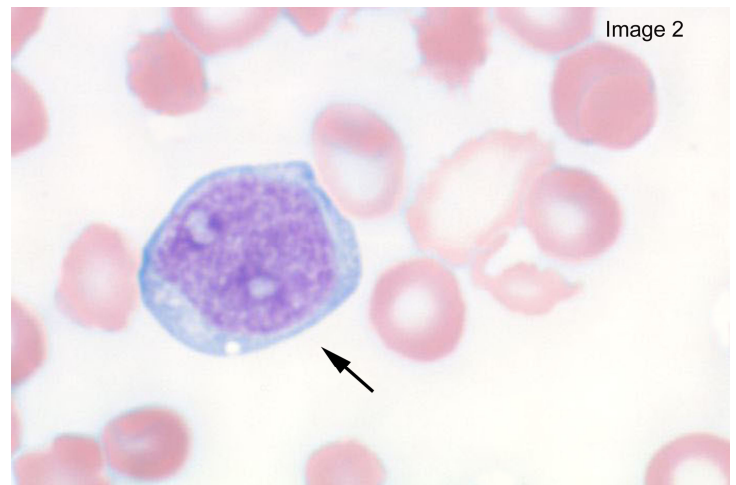
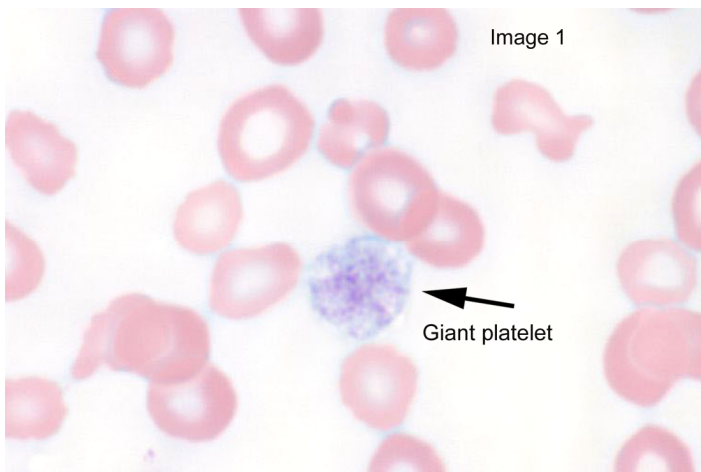
Slide 006	<i>Diagnosis:</i> Unknown	
<i>Available data:</i> 89 year-old female	WBC	4.9 x 10 ⁹ /L
	RBC	2.61 x 10 ¹² /L
	Hemoglobin	7.5 g/dL
	Hematocrit	22.2 %
	MCV	85.1 fL
	MCH	28.7 pg
	MCHC	33.8 g/dL
	RDW	19.9 %
	Platelet count	83 K/ μ L

Slide 006 was prepared from the peripheral blood obtained from an 89 year-old female following a packed red blood cell transfusion. A diagnosis was unavailable at the time of specimen collection.

The complete blood cell count in this case included decreased hemoglobin, hematocrit, red blood cell count and platelet count. Eighty percent (282) of participants correctly reported reduced number of platelets and giant platelets (Image 1) were reported present by 71% (252) of the participants. The red blood cell indices (MCV,

MCH, MCHC) were within normal range and abnormal morphology was reported by participants including acanthocytes (235 participants), echinocytes(145 participants) and schistocytes (248 participants). The indices suggest a normocytic/normochromic anemia. Possible causes of a normocytic/normochromic anemia with abnormal red blood cell morphology include microangiopathic hemolytic anemia, hemoglobinopathies, hereditary spherocytosis, autoimmune hemolytic anemia and some enzymatic deficiencies.

The white blood cell count was low normal and immature white blood cells including blast forms (Image 2) were reported by participants. The median count for blast cells, all types (blast cell; not classified, myeloblast, lymphoblast, monoblast) was 29 per 100 cells.



Slide: 006

<u>Cell Classification or Finding</u>	<u>Expected Range</u>	<u>Participant Median</u>	<u>Participant Range</u>
Blast cell not classified	11 - 43	28	0 - 43
Myeloblast/Promyelocyte	11 - 43	0	0 - 1
Lymphoblast/Prolymphocyte	11 - 43	0	0 - 0
Monoblast/Promonocyte	11 - 43	0	0 - 0
*[Blasts, all types]	11 - 43	29	5 - 43
Erythroblast	0 - 0	0	0 - 0
Lymphoma/Sezary cell	0 - 0	0	0 - 0
Hairy cell	0 - 0	0	0 - 0
Myelocyte	0 - 3	0	0 - 3
Metamyelocyte	0 - 3	0	0 - 4
Band neutrophil	1 - 26	11	0 - 28
Segmented neutrophil	14 - 48	33	10 - 49
*[Total neutrophils]	34 - 55	44	32 - 56
Eosinophil	0 - 2	0	0 - 2
Basophil	0 - 1	0	0 - 1
Lymphocyte	8 - 28	17	6 - 29
Atypical lymphocyte	0 - 10	0	0 - 11
Monocyte	0 - 12	5	0 - 12
Plasma cell	0 - 0	0	0 - 0
NRBC / 100 WBC	0 - 2	0	0 - 2

Erythrocyte Morphology

Expected Result

Participant Results

Anisocytosis	Moderate	None (6%) Slight (40%) Moderate (45%) Marked (5%)
Poikilocytosis	Moderate	None (15%) Slight (26%) Moderate (44%) Marked (11%)
Macrocytosis	None	None (67%) Slight (26%) Moderate (2%) Marked (0%)
Microcytosis	None	None (43%) Slight (37%) Moderate (14%) Marked (2%)
Hypochromia	Slight	None (29%) Slight (40%) Moderate (27%) Marked (3%)
Polychromasia	None	None (72%) Slight (26%) Moderate (1%) Marked (0%)

Cell Classification or Finding

Expected Result

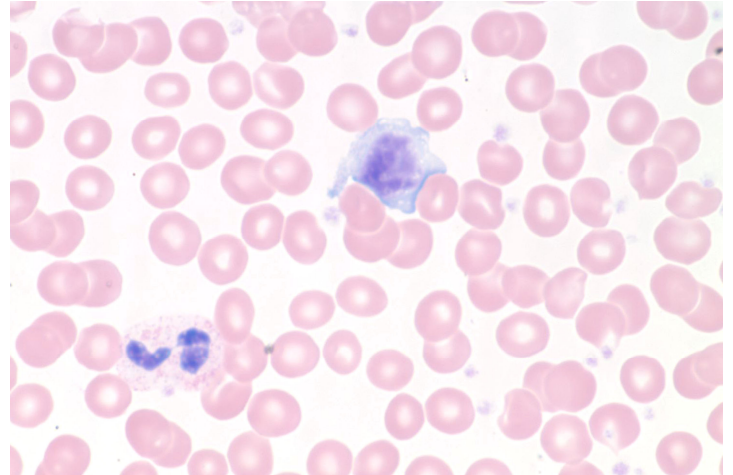
Participant Results

Reduced number of platelets	Present	Absent(20%) Present(80%)
Increased number of platelets	Absent	Absent(100%) Present(0%)
Phagocytosis of platelet(s)	Absent	Absent(100%) Present(0%)
Bizarre or irregular platelets	Absent	Absent(80%) Present(20%)
Clumped platelets	Absent	Absent(99%) Present(1%)
Giant platelets	Present	Absent(29%) Present(71%)
Platelet satellitosis	Absent	Absent(100%) Present(0%)
Auer rods	Absent	Absent(100%) Present(0%)
Dohle bodies	Absent	Absent(96%) Present(4%)
Hypersegmentation	Absent	Absent(100%) Present(0%)
Pelger Huet anomaly	Absent	Absent(96%) Present(4%)
Smudge / Basket cells	Absent	Absent(93%) Present(7%)
Toxic granulation	Absent	Absent(97%) Present(3%)
Acanthocytes	Present	Absent(33%) Present(67%)
Basophilic stippling	Absent	Absent(99%) Present(1%)
Blister cells (pre keratocytes)	Absent	Absent(98%) Present(2%)
Cabot rings	Absent	Absent(100%) Present(0%)
Echinocytes (crenated/burr cells)	Absent	Absent(59%) Present(41%)
Elliptocytes (ovalocytes)	Absent	Absent(70%) Present(30%)
Howell-Jolly bodies	Absent	Absent(100%) Present(0%)
Pappenheimer bodies	Absent	Absent(100%) Present(0%)
Red cell agglutinates	Absent	Absent(99%) Present(1%)
Rouleaux	Absent	Absent(95%) Present(5%)
Schistocytes	Present	Absent(30%) Present(70%)
Schuffner's granules	Absent	Absent(100%) Present(0%)
Sickle cells (drepanocytes)	Absent	Absent(100%) Present(0%)
Spherocytes	Absent	Absent(80%) Present(20%)
Stomatocytes	Absent	Absent(100%) Present(0%)
Target cells (codocytes)	Absent	Absent(99%) Present(1%)
Tear drop cells (dacrocytes)	Absent	Absent(91%) Present(9%)
Bacteria	Absent	Absent(99%) Present(1%)
Fungi/yeast	Absent	Absent(100%) Present(0%)
Malaria/Babesiosis	Absent	Absent(100%) Present(0%)
Stain precipitate	Absent	Absent(94%) Present(6%)
Phagocytosis of red cell(s)	Absent	Absent(100%) Present(0%)

NEW YORK STATE CYTOHEMATOLOGY PROFICIENCY TESTING PROGRAM
Glass Slide - November 2014

Results from this proficiency test event are available at:
<http://www.wadsworth.org/chemheme>

Slide 007	<i>Diagnosis:</i> None	
<i>Available data:</i> 59 year-old female	WBC	8.2 x 10 ⁹ /L
	RBC	4.67 x 10 ¹² /L
	Hemoglobin	14.1 g/dL
	Hematocrit	42.3 %
	MCV	90.7 fL
	MCH	30.3 pg
	MCHC	33.3 g/dL
	RDW	13.9 %
Platelet count	465 K/ μ L	



Slide 007 was prepared from the peripheral blood obtained from a 59 year-old female. All complete blood cell count parameters were within normal range and the 100-cell manual differential, as reported by participants, was unremarkable. A few atypical (reactive) lymphocytes (image) were reported by participants, the participant range for atypical lymphocytes was 0-14 and the participant median was three per 100 cells.

Slide: 007

<u>Cell Classification or Finding</u>	<u>Expected Range</u>	<u>Participant Median</u>	<u>Participant Range</u>
Blast cell not classified	0 - 0	0	0 - 0
Myeloblast/Promyelocyte	0 - 0	0	0 - 0
Lymphoblast/Prolymphocyte	0 - 0	0	0 - 0
Monoblast/Promonocyte	0 - 0	0	0 - 0
Erythroblast	0 - 0	0	0 - 0
Lymphoma/Sezary cell	0 - 0	0	0 - 0
Hairy cell	0 - 0	0	0 - 0
Myelocyte	0 - 1	0	0 - 1
Metamyelocyte	0 - 1	0	0 - 1
Band neutrophil	0 - 4	0	0 - 5
Segmented neutrophil	54 - 72	65	53 - 73
*[Total neutrophils]	57 - 73	66	56 - 74
Eosinophil	0 - 5	2	0 - 5
Basophil	0 - 2	0	0 - 2
Lymphocyte	10 - 30	21	10 - 31
Atypical lymphocyte	0 - 14	3	0 - 14
Monocyte	2 - 11	7	2 - 11
Plasma cell	0 - 0	0	0 - 0
NRBC / 100 WBC	0 - 0	0	0 - 0

Erythrocyte Morphology

<u>Expected Result</u>	<u>Participant Results</u>
Anisocytosis	None (80%) Slight (13%) Moderate (0%) Marked (0%)
Poikilocytosis	None (87%) Slight (3%) Moderate (0%) Marked (0%)
Macrocytosis	None (87%) Slight (6%) Moderate (1%) Marked (0%)
Microcytosis	None (90%) Slight (3%) Moderate (0%) Marked (0%)
Hypochromia	None (98%) Slight (2%) Moderate (0%) Marked (0%)
Polychromasia	None (99%) Slight (1%) Moderate (0%) Marked (0%)

Cell Classification or Finding

<u>Expected Result</u>	<u>Participant Results</u>
Reduced number of platelets	Absent (99%) Present(1%)
Increased number of platelets	Absent(69%) Present(31%)
Phagocytosis of platelet(s)	Absent(100%) Present(0%)
Bizarre or irregular platelets	Absent(100%) Present(0%)
Clumped platelets	Absent(99%) Present(1%)
Giant platelets	Absent(91%) Present(9%)
Platelet satellitosis	Absent(100%) Present(0%)
Auer rods	Absent(100%) Present(0%)
Dohle bodies	Absent(100%) Present(0%)
Hypersegmentation	Absent(94%) Present(6%)
Pelger Huet anomaly	Absent(100%) Present(0%)
Smudge / Basket cells	Absent(100%) Present(0%)
Toxic granulation	Absent(99%) Present(1%)
Acanthocytes	Absent(100%) Present(0%)
Basophilic stippling	Absent(100%) Present(0%)
Blister cells (pre keratocytes)	Absent(100%) Present(0%)
Cabot rings	Absent(100%) Present(0%)
Echinocytes (crenated/burr cells)	Absent(100%) Present(0%)
Elliptocytes (ovalocytes)	Absent(97%) Present(3%)
Howell-Jolly bodies	Absent(100%) Present(0%)
Pappenheimer bodies	Absent(100%) Present(0%)
Red cell agglutinates	Absent(100%) Present(0%)
Rouleaux	Absent(99%) Present(1%)
Schistocytes	Absent(100%) Present(0%)
Schuffner's granules	Absent(100%) Present(0%)
Sickle cells (drepanocytes)	Absent(100%) Present(0%)
Spherocytes	Absent(99%) Present(1%)
Stomatocytes	Absent(95%) Present(5%)
Target cells (codocytes)	Absent(100%) Present(0%)
Tear drop cells (dacrocytes)	Absent(100%) Present(0%)
Bacteria	Absent(100%) Present(0%)
Fungi/yeast	Absent(100%) Present(0%)
Malaria/Babesiosis	Absent(100%) Present(0%)
Stain precipitate	Absent(99%) Present(1%)
Phagocytosis of red cell(s)	Absent(100%) Present(0%)

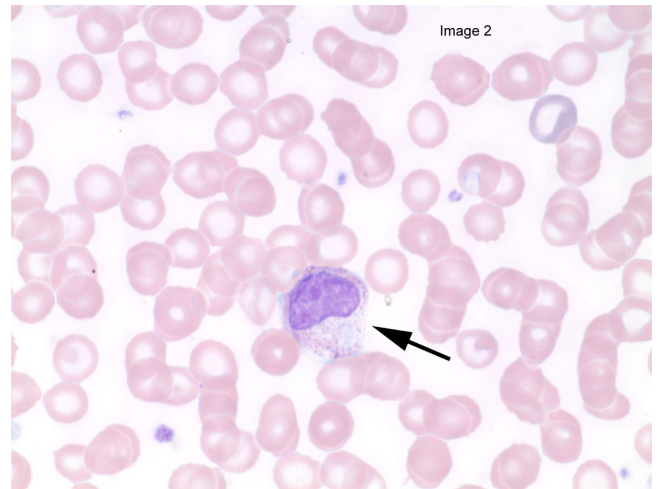
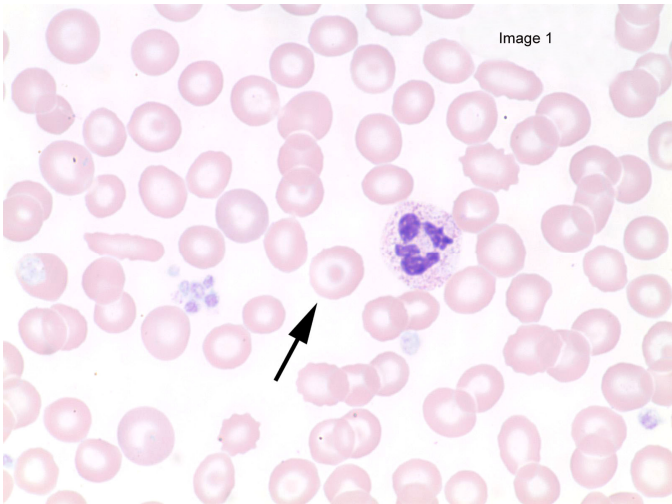
NEW YORK STATE CYTOHEMATOLOGY PROFICIENCY TESTING PROGRAM
Glass Slide - November 2014

Results from this proficiency test event are available at:
<http://www.wadsworth.org/chemheme>

Slide 008	<i>Diagnosis:</i> Unknown	
<i>Available data:</i> 70 year-old female	WBC	17.7 x 10 ⁹ /L
	RBC	4.09 x 10 ¹² /L
	Hemoglobin	11.2 g/dL
	Hematocrit	32.9 %
	MCV	80.4 fL
	MCH	27.4 pg
	MCHC	34.0 g/dL
	RDW	15.6 %
	Platelet count	127 K/ μ L

Slide 008 was prepared from the peripheral blood obtained from a 70 year-old female with an unknown diagnosis. The clinically significant findings present in this case, as reported by participants, included target cells (Image 1), macrocytosis, hypochromasia, and polychromasia. A polychromatophilic red blood cell can be seen in Image 2 (approximate two o'clock), eighty-five percent of participants reported slight to moderate polychromasia.

Participants also reported the presence of immature white blood cells, including myelocyte, metamyelocyte (Image 2) and band forms. The participant range for myelocyte was 0 - 5, metamyelocyte was 0 - 4 and band neutrophil was 0 – 10 per 100 cells.



Slide: 008

<u>Cell Classification or Finding</u>	<u>Expected Range</u>	<u>Participant Median</u>	<u>Participant Range</u>
Blast cell not classified	0 - 0	0	0 - 1
Myeloblast/Promyelocyte	0 - 0	0	0 - 1
Lymphoblast/Prolymphocyte	0 - 0	0	0 - 1
Monoblast/Promonocyte	0 - 0	0	0 - 1
*[Blasts, all types]	0 - 0	0	0 - 1
Erythroblast	0 - 0	0	0 - 0
Lymphoma/Sezary cell	0 - 0	0	0 - 0
Hairy cell	0 - 0	0	0 - 0
Myelocyte	0 - 5	1	0 - 5
Metamyelocyte	0 - 3	1	0 - 4
Band neutrophil	0 - 10	2	0 - 10
Segmented neutrophil	69 - 88	79	67 - 88
*[Total neutrophils]	75 - 90	82	74 - 90
Eosinophil	0 - 2	1	0 - 2
Basophil	0 - 1	0	0 - 1
Lymphocyte	1 - 11	7	1 - 12
Atypical lymphocyte	0 - 4	0	0 - 4
Monocyte	2 - 11	7	2 - 11
Plasma cell	0 - 0	0	0 - 0
NRBC / 100 WBC	0 - 1	0	0 - 1

Erythrocyte Morphology

<u>Expected Result</u>	<u>Participant Results</u>
Anisocytosis	Slight None (36%) Slight (54%) Moderate (5%) Marked (0%)
Poikilocytosis	None None (71%) Slight (18%) Moderate (2%) Marked (1%)
Macrocytosis	None None (61%) Slight (25%) Moderate (9%) Marked (0%)
Microcytosis	None None (77%) Slight (16%) Moderate (2%) Marked (0%)
Hypochromia	Slight None (24%) Slight (48%) Moderate (23%) Marked (5%)
Polychromasia	Slight None (14%) Slight (79%) Moderate (6%) Marked (0%)

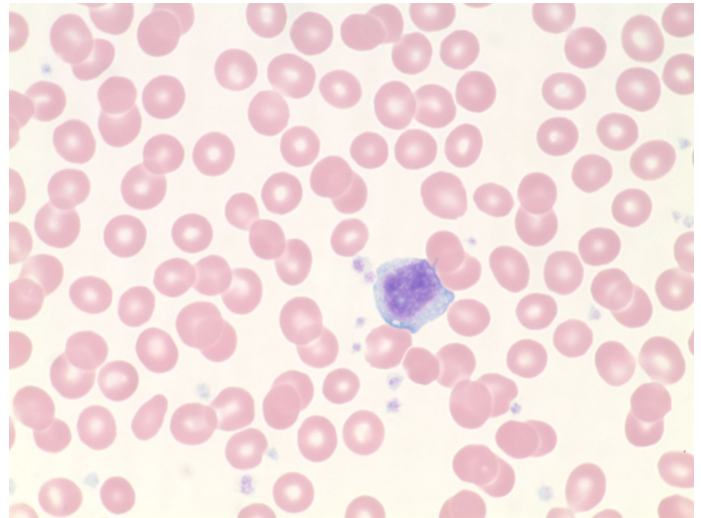
Cell Classification or Finding

<u>Expected Result</u>	<u>Participant Results</u>
Reduced number of platelets	Absent(65%) Present(35%)
Increased number of platelets	Absent(99%) Present(1%)
Phagocytosis of platelet(s)	Absent(100%) Present(0%)
Bizarre or irregular platelets	Absent(98%) Present(2%)
Clumped platelets	Absent(96%) Present(4%)
Giant platelets	Present(49%) Present(51%)
Platelet satellitosis	Absent(100%) Present(0%)
Auer rods	Absent(100%) Present(0%)
Dohle bodies	Absent(99%) Present(1%)
Hypersegmentation	Absent(92%) Present(8%)
Pelger Huet anomaly	Absent(100%) Present(0%)
Smudge / Basket cells	Absent(91%) Present(9%)
Toxic granulation	Absent(78%) Present(22%)
Acanthocytes	Absent(100%) Present(0%)
Basophilic stippling	Absent(93%) Present(7%)
Blister cells (pre keratocytes)	Absent(100%) Present(0%)
Cabot rings	Absent(100%) Present(0%)
Echinocytes (crenated/burr cells)	Absent(97%) Present(3%)
Elliptocytes (ovalocytes)	Absent(97%) Present(3%)
Howell-Jolly bodies	Absent(99%) Present(1%)
Pappenheimer bodies	Absent(100%) Present(0%)
Red cell agglutinates	Absent(100%) Present(0%)
Rouleaux	Absent(98%) Present(2%)
Schistocytes	Absent(99%) Present(1%)
Schuffner's granules	Absent(100%) Present(0%)
Sickle cells (drepanocytes)	Absent(100%) Present(0%)
Spherocytes	Absent(99%) Present(1%)
Stomatocytes	Absent(99%) Present(1%)
Target cells (codocytes)	Present(16%) Present(84%)
Tear drop cells (dacrocytes)	Absent(97%) Present(3%)
Bacteria	Absent(100%) Present(0%)
Fungi/yeast	Absent(100%) Present(0%)
Malaria/Babesiosis	Absent(99%) Present(1%)
Stain precipitate	Absent(94%) Present(6%)
Phagocytosis of red cell(s)	Absent(100%) Present(0%)

NEW YORK STATE CYTOHEMATOLOGY PROFICIENCY TESTING PROGRAM
Glass Slide - November 2014

Results from this proficiency test event are available at:
<http://www.wadsworth.org/chemheme>

Slide 009	<i>Diagnosis:</i> None	
<i>Available data:</i> 50 year-old female	WBC	5.1 x 10 ⁹ /L
	RBC	4.43 x 10 ¹² /L
	Hemoglobin	13.5 g/dL
	Hematocrit	39.2 %
	MCV	88.5 fL
	MCH	30.5 pg
	MCHC	34.5 g/dL
	RDW	14.8 %
	Platelet count	245 K/ μ L



Slide 009 was prepared from the peripheral blood obtained from a 50 year-old asymptomatic female. As expected, no clinically significant findings were reported by participants. Atypical (reactive) lymphocytes (image) were reported by participants; the participant median for atypical lymphocyte was three per 100 cells.

Slide: 009

<u>Cell Classification or Finding</u>	<u>Expected Range</u>	<u>Participant Median</u>	<u>Participant Range</u>
Blast cell not classified	0 - 0	0	0 - 0
Myeloblast/Promyelocyte	0 - 0	0	0 - 0
Lymphoblast/Prolymphocyte	0 - 0	0	0 - 0
Monoblast/Promonocyte	0 - 0	0	0 - 0
Erythroblast	0 - 0	0	0 - 0
Lymphoma/Sezary cell	0 - 0	0	0 - 0
Hairy cell	0 - 0	0	0 - 0
Myelocyte	0 - 0	0	0 - 0
Metamyelocyte	0 - 0	0	0 - 0
Band neutrophil	0 - 5	1	0 - 5
Segmented neutrophil	40 - 58	50	38 - 59
*[Total neutrophils]	41 - 59	51	41 - 61
Eosinophil	1 - 8	4	1 - 8
Basophil	0 - 2	0	0 - 2
Lymphocyte	22 - 45	35	21 - 46
Atypical lymphocyte	0 - 12	3	0 - 13
Monocyte	1 - 10	6	1 - 10
Plasma cell	0 - 0	0	0 - 0
NRBC / 100 WBC	0 - 0	0	0 - 0

Erythrocyte Morphology

<u>Expected Result</u>	<u>Participant Results</u>
Anisocytosis	None (74%) Slight (18%) Moderate (1%) Marked (0%)
Poikilocytosis	None (87%) Slight (3%) Moderate (0%) Marked (0%)
Macrocytosis	None (89%) Slight (4%) Moderate (0%) Marked (0%)
Microcytosis	None (88%) Slight (4%) Moderate (1%) Marked (0%)
Hypochromia	None (97%) Slight (3%) Moderate (0%) Marked (0%)
Polychromasia	None (99%) Slight (1%) Moderate (0%) Marked (0%)

Cell Classification or Finding

<u>Expected Result</u>	<u>Participant Results</u>
Reduced number of platelets	Absent(99%) Present(1%)
Increased number of platelets	Absent(97%) Present(3%)
Phagocytosis of platelet(s)	Absent(100%) Present(0%)
Bizarre or irregular platelets	Absent(99%) Present(1%)
Clumped platelets	Absent(99%) Present(1%)
Giant platelets	Absent(83%) Present(17%)
Platelet satellitosis	Absent(100%) Present(0%)
Auer rods	Absent(100%) Present(0%)
Dohle bodies	Absent(100%) Present(0%)
Hypersegmentation	Absent(99%) Present(1%)
Pelger Huet anomaly	Absent(100%) Present(0%)
Smudge / Basket cells	Absent(99%) Present(1%)
Toxic granulation	Absent(98%) Present(2%)
Acanthocytes	Absent(100%) Present(0%)
Basophilic stippling	Absent(100%) Present(0%)
Blister cells (pre keratocytes)	Absent(100%) Present(0%)
Cabot rings	Absent(100%) Present(0%)
Echinocytes (crenated/burr cells)	Absent(100%) Present(0%)
Elliptocytes (ovalocytes)	Absent(93%) Present(7%)
Howell-Jolly bodies	Absent(100%) Present(0%)
Pappenheimer bodies	Absent(100%) Present(0%)
Red cell agglutinates	Absent(100%) Present(0%)
Rouleaux	Absent(95%) Present(5%)
Schistocytes	Absent(100%) Present(0%)
Schuffner's granules	Absent(100%) Present(0%)
Sickle cells (drepanocytes)	Absent(100%) Present(0%)
Spherocytes	Absent(99%) Present(1%)
Stomatocytes	Absent(99%) Present(1%)
Target cells (codocytes)	Absent(100%) Present(0%)
Tear drop cells (dacrocytes)	Absent(99%) Present(1%)
Bacteria	Absent(100%) Present(0%)
Fungi/yeast	Absent(100%) Present(0%)
Malaria/Babesiosis	Absent(100%) Present(0%)
Stain precipitate	Absent(99%) Present(1%)
Phagocytosis of red cell(s)	Absent(100%) Present(0%)

NEW YORK STATE CYTOHEMATOLOGY PROFICIENCY TESTING PROGRAM
Glass Slide - November 2014

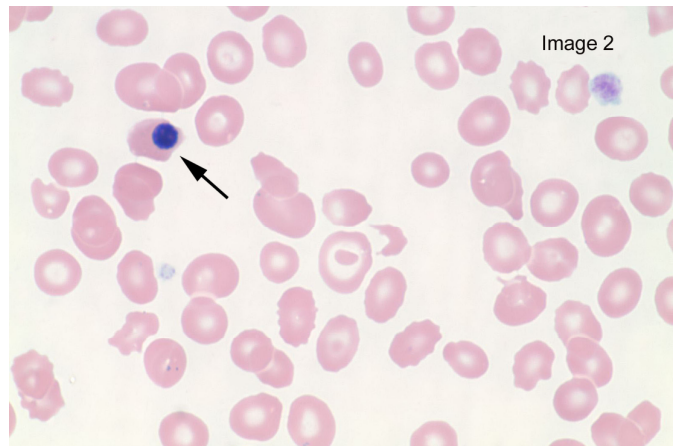
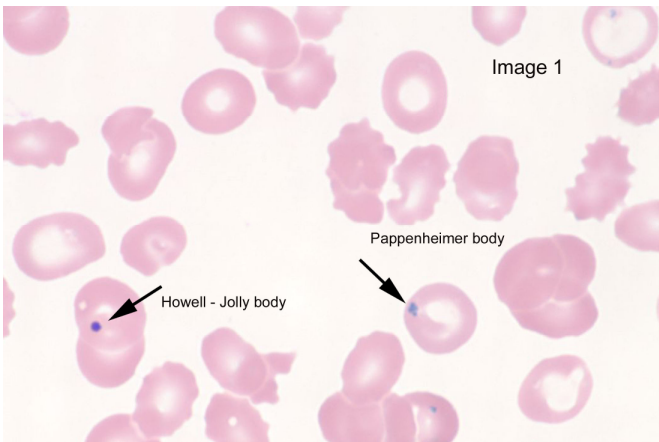
Results from this proficiency test event are available at:
<http://www.wadsworth.org/chemheme>

Slide 010	<i>Diagnosis:</i> Aggressive multiple myeloma with renal failure	
<i>Available data:</i> 60 year-old male	WBC	6.3 x 10 ⁹ /L
	RBC	2.34 x 10 ¹² /L
	Hemoglobin	7.6 g/dL
	Hematocrit	23.1 %
	MCV	98.7 fL
	MCH	32.5 pg
	MCHC	32.9 g/dL
	RDW	23.7 %
	Platelet count	26 K/ μ L

Slide 010 was prepared from the peripheral blood obtained from a 60 year-old male. The diagnosis provided was aggressive multiple myeloma with renal failure. A decreased hemoglobin and hematocrit in a case of multiple myeloma with renal insufficiency, as presented here, is common due in part to erythropoietin (EPO) deficiency and the myelosuppressive effect of chemotherapy.

The platelet count in this case was 26 K/ μ L and reduced number of platelets was correctly identified by 300 (85%) of participants. Additional findings reported by participants included echinocytes, elliptocytes, Howell-

Jolly bodies (Image 1), Pappenheimer bodies (Image 1), nucleated red blood cells (Image 2), schistocytes and target cells.



Slide: 010

<u>Cell Classification or Finding</u>	<u>Expected Range</u>	<u>Participant Median</u>	<u>Participant Range</u>
Blast cell not classified	0 - 0	0	0 - 0
Myeloblast/Promyelocyte	0 - 0	0	0 - 0
Lymphoblast/Prolymphocyte	0 - 0	0	0 - 0
Monoblast/Promonocyte	0 - 0	0	0 - 0
Erythroblast	0 - 0	0	0 - 0
Lymphoma/Sezary cell	0 - 0	0	0 - 0
Hairy cell	0 - 0	0	0 - 0
Myelocyte	0 - 0	0	0 - 0
Metamyelocyte	0 - 0	0	0 - 1
Band neutrophil	0 - 9	2	0 - 10
Segmented neutrophil	76 - 95	88	74 - 95
*[Total neutrophils]	83 - 96	91	82 - 96
Eosinophil	0 - 1	0	0 - 1
Basophil	0 - 0	0	0 - 0
Lymphocyte	0 - 10	5	0 - 10
Atypical lymphocyte	0 - 1	0	0 - 1
Monocyte	0 - 8	4	0 - 8
Plasma cell	0 - 0	0	0 - 0
NRBC / 100 WBC	2 - 17	10	0 - 19

Erythrocyte Morphology

Expected Result

Participant Results

Anisocytosis	Moderate	None (3%) Slight (11%) Moderate (55%) Marked (28%)
Poikilocytosis	Moderate	None (9%) Slight (16%) Moderate (54%) Marked (16%)
Macrocytosis	Slight	None (18%) Slight (39%) Moderate (37%) Marked (3%)
Microcytosis	None	None (43%) Slight (41%) Moderate (12%) Marked (0%)
Hypochromia	None	None (43%) Slight (35%) Moderate (20%) Marked (2%)
Polychromasia	None	None (84%) Slight (16%) Moderate (1%) Marked (0%)

Cell Classification or Finding

Expected Result

Participant Results

Reduced number of platelets	Present	Absent(15%) Present(85%)
Increased number of platelets	Absent	Absent(100%) Present(0%)
Phagocytosis of platelet(s)	Absent	Absent(100%) Present(0%)
Bizarre or irregular platelets	Absent	Absent(98%) Present(2%)
Clumped platelets	Absent	Absent(100%) Present(0%)
Giant platelets	Absent	Absent(75%) Present(25%)
Platelet satellitosis	Absent	Absent(100%) Present(0%)
Auer rods	Absent	Absent(100%) Present(0%)
Dohle bodies	Absent	Absent(98%) Present(2%)
Hypersegmentation	Absent	Absent(100%) Present(0%)
Pelger Huet anomaly	Absent	Absent(86%) Present(14%)
Smudge / Basket cells	Absent	Absent(97%) Present(3%)
Toxic granulation	Absent	Absent(97%) Present(3%)
Acanthocytes	Present	Absent(44%) Present(56%)
Basophilic stippling	Absent	Absent(73%) Present(27%)
Blister cells (pre keratocytes)	Absent	Absent(99%) Present(1%)
Cabot rings	Absent	Absent(100%) Present(0%)
Echinocytes (crenated/burr cells)	Present	Absent(27%) Present(73%)
Elliptocytes (ovalocytes)	Present	Absent(25%) Present(75%)
Howell-Jolly bodies	Present	Absent(20%) Present(80%)
Pappenheimer bodies	Absent	Absent(63%) Present(37%)
Red cell agglutinates	Absent	Absent(100%) Present(0%)
Rouleaux	Absent	Absent(97%) Present(3%)
Schistocytes	Present	Absent(17%) Present(83%)
Schuffner's granules	Absent	Absent(100%) Present(0%)
Sickle cells (drepanocytes)	Absent	Absent(96%) Present(4%)
Spherocytes	Absent	Absent(60%) Present(40%)
Stomatocytes	Absent	Absent(98%) Present(2%)
Target cells (codocytes)	Absent	Absent(61%) Present(39%)
Tear drop cells (dacrocytes)	Absent	Absent(91%) Present(9%)
Bacteria	Absent	Absent(100%) Present(0%)
Fungi/yeast	Absent	Absent(100%) Present(0%)
Malaria/Babesiosis	Absent	Absent(97%) Present(3%)
Stain precipitate	Absent	Absent(99%) Present(1%)
Phagocytosis of red cell(s)	Absent	Absent(100%) Present(0%)